

Odontogenic Keratocyst of Maxillary Premolar Region: A Case Report

N K Suma¹, C Pinky², N S Venkatesh Babu³, Smriti Jha⁴

¹Reader, Department of Pediatric and Preventive Dentistry, V S Dental College and Hospital, Bengaluru, Karnataka, India, ²Senior Lecturer, Department of Pediatric and Preventive dentistry, KGF Dental College and Hospital, Kolar, Karnataka, India, ³Professor and Head, Department of Pediatric and Preventive Dentistry, V S Dental College and Hospital, Bengaluru, Karnataka, India, ⁴Post Graduate Student, Department of Pediatric and Preventive Dentistry, V S Dental College and Hospital, Bengaluru, India

Odontogenic keratocysts (OKC) are enamel organ or dental lamina derived cysts and are not thought to be associated with any infection. They mainly occur in second and third decades of life. The purpose of this case report is to describe a rare case of OKC in a 10-year-old girl, associated with upper left unerupted maxillary first premolar. It involved maxillary sinus leading to erosion of left orbital floor. It also led to the displacement of adjacent maxillary canine and maxillary left second premolar above the unerupted maxillary left third molar. Due to the aggressive nature of the cyst, it was enucleated and followed-up.

Keywords: Displaced second premolar, Eroded orbital floor, Odontogenic keratocyst

INTRODUCTION

Jaw cysts are very common due to the presence of odontogenic epithelial remnants in the jaws. Cysts constitute about 17% of the total tissue specimens that are submitted to oral pathology for biopsy.¹

Odontogenic keratocysts (OKC) are epithelial developmental cysts, which were first described by Philipsen in 1953.² However, the main features of OKCs were described in 1963 by Pindborg and Hansen.³

OKCs have been reported to account for 3-10.5% of all the jaw cysts. They mainly occur in second and third decades of life. In general, OKCs are solitary lesions unless they are associated with nevoid basal cell carcinoma syndrome. Although, they can occur in any part of the jaw, majority of lesions occur in the mandible, most commonly in the posterior body and ascending ramus.²

OKCs are thought to be derived from the enamel organ or from the dental lamina and are probably not related to

any kind of infection. Clinically, they do not present any characteristic features. Although, they grow to reach a large size when compared to other jaw cysts, they may remain asymptomatic. When they do manifest clinically, intraoral drainage and swelling are the most common findings. It is of interest that these cysts more often penetrate the bone rather than expand.³

Here, we present a rare case of an OKC associated with unerupted first maxillary premolar leading to displacement of the second premolar in a 10-year-old girl. The lesion was enucleated under general anesthesia and followed up post operatively.

CASE REPORT

A 10-year-old girl, reported to the outpatient department of our college, with the chief complaint of swelling on the left side of the cheek. About 2 weeks earlier, parents noticed the swelling and had visited a private dental clinic for the same. There it was thought to be an abscess and was treated with antibiotics, but the swelling did not subside. They were then referred to our institution.

Patient presented with swelling on the left cheek (Figure 1). The swelling was bony hard on extra oral examination. Intraoral examination was painless and revealed expansion of buccal cortical bone, with egg-shell crackling on palpation. Vestibule was obliterated, and slight palatal swelling was evident. Patient had very good oral hygiene

Access this article online



www.ijsscr.com

Month of Submission : 12-2014
 Month of Peer Review : 01-2015
 Month of Acceptance : 01-2015
 Month of Publishing : 02-2015

Corresponding Author:

Dr. N K Suma, Department of Pediatric and Preventive Dentistry, VS Dental College and Hospital, K R Road, V V Puram, Bengaluru, Karnataka, India. Phone: +91-9986459932. E-mail: drsnkdec14@yahoo.co.in

(Figure 2). General physical examination was carried out to rule out basal cell nevus syndrome.

Orthopantomogram was taken (Figure 3). Radiographic examination revealed a wide radiolucent lesion in relation to maxillary first premolar encroaching on the maxillary sinus and eroding the floor of the orbit. There was displacement of maxillary second premolar, apical to unerupted maxillary third molar.

A provisional diagnosis of OKC was made on the findings of early involvement of cortical plates, and radiographic features. The diagnosis was later confirmed by histologic examination of the enucleated specimen.

Under general anesthesia, labial and buccal flaps were reflected, and the cyst was enucleated along with extraction of the second premolar due its extreme displacement. However, it was decided to leave the first premolar in place considering young age of the patient.

The specimen was submitted for histopathologic examination, which confirmed the diagnosis of OKC.

Histologic examination revealed a lining of uniformly thin parakeratinized epithelium with a prominent palisaded basal cell layer. The cyst was filled with keratin. There were very few inflammatory cells in the thin fibrous wall (Figure 4).

Patient was recalled after 8 days and the wound seemed to be healing uneventfully (Figure 5).

DISCUSSION

OKCs involve the cancellous bone and tend to enlarge it to considerable size before any significant buccal or lingual expansion appears. This prevents an early diagnosis of an underlying lesion. Donoff et al attributed the ability of keratocysts to grow expansively within bone to the collagenase activity in keratocyst epithelium.⁴

OKCs are locally destructive jaw lesions and must be distinguished from the other jaw cysyts. The diagnosis of the lesion can be confirmed only by histologic examination. This is because the since the appearances of the cyst on

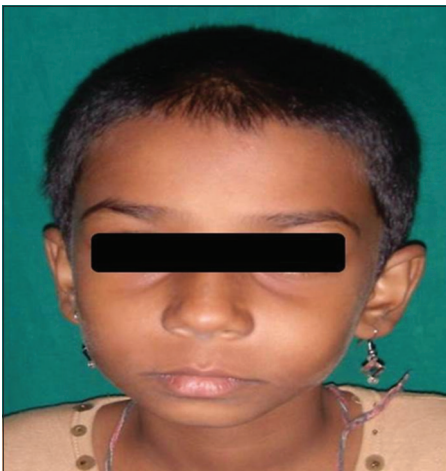

Figure 1: Extra oral view of the patient showing diffuse swelling over the left cheek

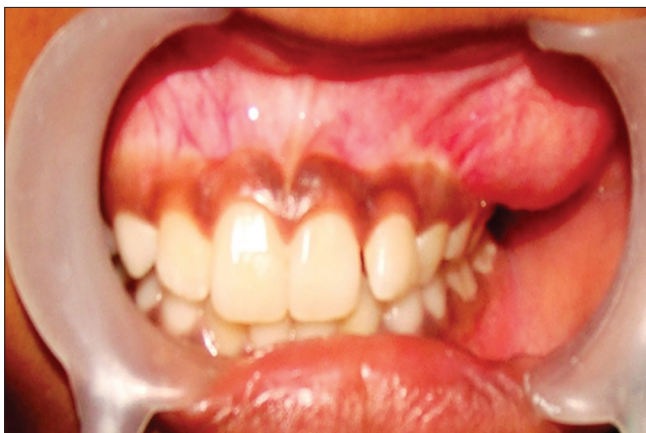

Figure 2: Intraoral photograph showing buccal extent of the lesion

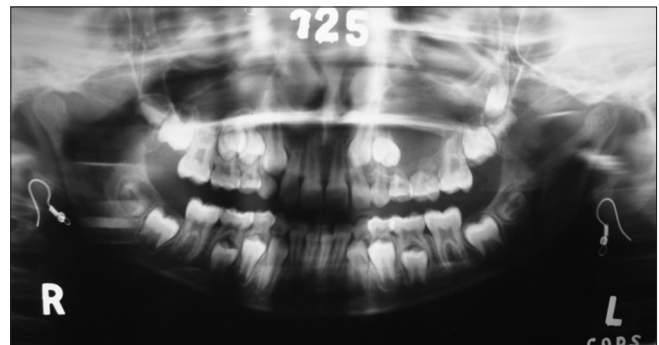


Figure 3: Orthopantomogram showing unilocular radiolucency involving maxillary sinus leading to erosion of the orbital floor and displacement of adjacent canine and maxillary second premolar apical to unerupted maxillary third molar

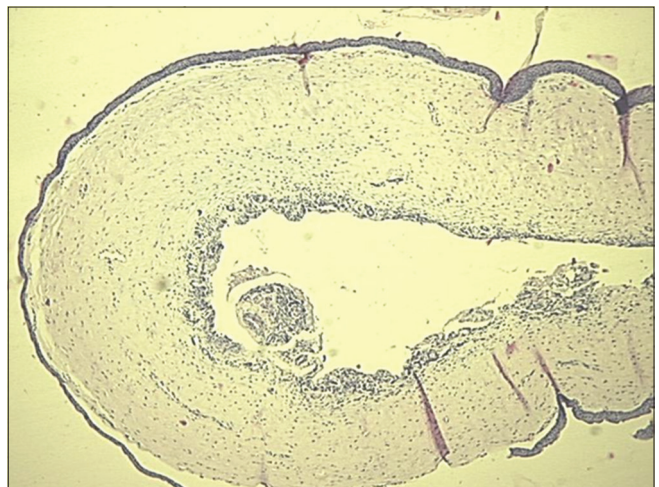

Figure 4: Histology showing a cyst filled with keratin, and lined with uniformly thin parakeratinised epithelium with a prominent palisaded basal cell layer

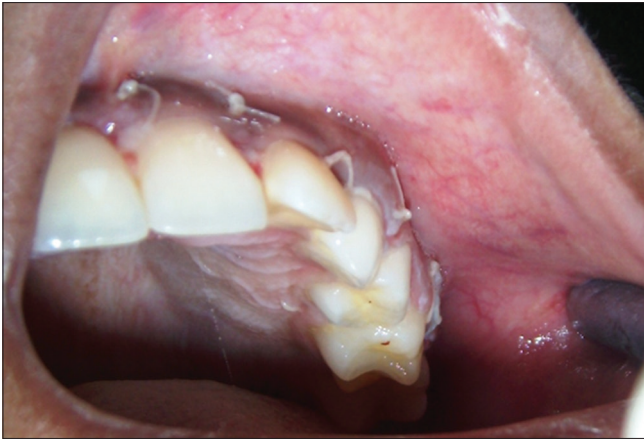

Figure 5: Intraoral photograph 8 days after surgery showed uneventful healing

roentgenograms and clinically usually do not reveal the true nature of the lesion.⁵

One of the characteristic features of OKC is recurrence. Donoff *et al.* associated recurrence of OKC with increased activity of epithelial lining and observed separation of the epithelium from the underlying connective tissue. They hypothesized that the enzymatic activity within the cyst might be responsible for the observed epithelial separation.⁴ Brannon, in his review of 312 OKCs, suggested three mechanisms responsible for recurrence: remnants of dental lamina within the jaws not associated with the original OKC, incomplete removal of the original cystic lining and cortical perforation with adherence to adjacent soft tissue, and cell rests of dental lamina and satellite cysts that remain behind after enucleation.^{6,7}

Vedtofte and Praetorius, in their review of 72 patients with 75 OKCs, found that the remnants of dental lamina remained between the cystic membrane and the overlying mucosa. Therefore, in accordance with other investigators, they advocated excision of the overlying mucosa in conjunction with the removal of cyst.⁸

It is also well-known that OKCs frequently recur after enucleation, particularly within first 5 years.⁹ Parakeratinized OKCs are associated with higher recurrence rate when compared to orthokeratinized OKCs.² Although, complete enucleation of the keratocyst including the associated tooth decreases the recurrence rate, the procedure often causes morbidity. It has therefore been advocated that marsupialization is a better alternative for the treatment of OKCs.⁹

Various factors influence the choice of treatment for a given patient as enumerated by Bramley, Eyre, Zakrzewska and Irvine. The treatment decisions are based on the age and health of the patient, size, and location of the lesion, involvement of the cortical bone, and presence of important

anatomical structures in close proximity to the lesion. Bramley gave three treatment options according to the size and location, which he outlined as: Intraoral enucleation for unilocular cysts, decompression and secondary enucleation in areas of difficult access, and resection and primary bone grafting for large multilocular cysts.

Partridge advocated marsupialization of the lesion, and he observed a decrease in an aggressive nature of the keratocysts once they were decompressed. However, the major drawback of this approach was that pathologic tissue was intentionally left behind. This was associated with increased potential for developing satellite cysts in the fibrous wall of the primary cyst cavity.¹⁰

Voorsmit and Stoelinga, on the other hand gave the following treatment outline: Enucleation for unilocular keratocyst with removal of overlying tissue and cauterization of the cavity with Carnoy's solution, Caldwell-Luc approach for keratocysts of maxillary sinus with selective cauterization avoiding vital structures, enucleation and cauterization of multilocular cysts, and enucleation and removal of overlying mucosa and cauterization for keratocysts of ascending ramus region.¹¹

It was noted by Attenborough that recurrence was involved with bone grafts. He assumed that the cystic cells invade the graft from remaining mandible or surface soft tissues.

In such cases as suggested by Voorsmit and Stoelinga, it is recommended to excise the soft tissue overlying the lesion following resection of the mandible. This is then followed by chemical cauterization of the surrounding soft and hard tissue with Carnoy's solution.¹¹

OKCs involving the posterior maxilla or those with significant cortical perforation should be viewed with great concern because reports have demonstrated the ability of this cyst to extend into adjacent areas.¹²

Whenever a child of younger age group presents with more than one OKC, regardless of apparent family history, one should suspect the possibility of a nevoid basal cell carcinoma syndrome.¹²

OKC's also have a rare but reported an incidence of malignant transformation to Squamous cell carcinoma, but none of those have been reported in children.¹³

CONCLUSION

OKCs have been a subject of much controversy over the last 50 years with respect to their origin, growth, and treatment modalities. With regard to the case presented in this paper,

our treatment plan involved enucleation of the cyst with retention of first premolar, giving consideration to the young age of the patient and with clinical and radiographic follow-up subsequently.

REFERENCES

1. Ali M, Baughman RA. Maxillary odontogenic keratocyst: a common and serious clinical misdiagnosis. *J Am Dent Assoc* 2003;134:877-83.
2. Chirapathomsakul D, Sastravaha P, Jansisyanont P. A review of odontogenic keratocysts and the behavior of recurrences. *Oral Surg Oral Med Oral Pathol Oral Radiol Endod* 2006;101:5-9.
3. Zachariades N, Papanicolaou S, Triantafyllou D. Odontogenic keratocysts: review of the literature and report of sixteen cases. *J Oral Maxillofac Surg* 1985;43:177-82.
4. Donoff RB, Guralnick WC, Clayman L. Keratocysts of the jaws. *J Oral Surg* 1972;30:880-4.
5. Ebenzar V, Balakrishnan R, Sivakumar M. A case report on surgical management of odontogenic keartocyst. *World J Med Sci* 2014;10:212-6.
6. Brannon RB. The odontogenic keratocyst. A clinicopathologic study of 312 cases. Part I. Clinical features. *Oral Surg Oral Med Oral Pathol* 1976;42:54-72.
7. Brannon RB. The odontogenic keratocyst. A clinicopathologic study of 312 cases. Part II. Histologic features. *Oral Surg Oral Med Oral Pathol* 1977;43:233-55.
8. Vedtofte P, Praetorius F. Recurrence of the odontogenic keratocyst in relation to clinical and histological features. A 20-year follow-up study of 72 patients. *Int J Oral Surg* 1979;8:412-20.
9. Tanimoto Y, Miyawaki S, Imai M, Takeda R, Takano-Yamamoto T. Orthodontic treatment of a patient with an impacted maxillary second premolar and odontogenic keratocyst in the maxillary sinus. *Angle Orthod* 2005;75:1077-83.
10. Partridge M, Towers JF. The primordial cyst (odontogenic keratocyst): its tumour-like characteristics and behaviour. *Br J Oral Maxillofac Surg* 1987;25:271-9.
11. Voorsmit RA, Stoelinga PJ, van Haelst UJ. The management of keratocysts. *J Maxillofac Surg* 1981;9:228-36.
12. Dowling PA, Fleming P, Saunders ID, Gorlin RJ, Napier SS. Odontogenic keratocysts in a 5-year-old: initial manifestations of nevoid basal cell carcinoma syndrome. *Pediatr Dent* 2000;22:53-5.
13. Meara JG, Li KK, Shah SS, Cunningham MJ. Odontogenic keratocysts in the pediatric population. *Arch Otolaryngol Head Neck Surg* 1996;122:725-8.

How to cite this article: Suma NK, Pinky C, Babu NS, Jha S. Odontogenic Keratocyst of Maxillary Premolar Region: A Case Report. *IJSS Case Reports & Reviews* 2015;1(9):38-41.

Source of Support: Nil, **Conflict of Interest:** None declared.