

Optic Nerve Glioma with Unilateral Proptosis: An Interesting Case Report

Shubhra Mehta¹, Anishi Agrawal², Amandeep Chawla²

¹Associate Professor, Department of Ophthalmology, R.D. Gardi Medical College, Ujjain, Madhya Pradesh, India, ²Post Graduate Student, Department of Ophthalmology, R.D. Gardi Medical College, Ujjain, Madhya Pradesh, India.

Optic nerve is most important cranial nerve responsible for visual functioning. Optic nerve involvement leading to blindness can be seen in various diseases, which cause swelling, inflammation, ischemia of the optic nerve. The optic nerve glioma (ONG) comprises 5% of all pediatric intracranial tumor and are a leading cause of unilateral proptosis. ONGs can be associated with neurofibromatosis and are more common than meningiomas. 20-30% of ONGs become symptomatic before the age of 10 years. Visual evoked potential testing is helpful in detecting asymptomatic gliomas. Early detection and prompt management can prevent blindness from gliomas. Treatment of ONG should be tailored to the individual patient. Our patient also showed the presence of unilateral ONG with proptosis. Magnetic resonance imaging was diagnostic. Partial optic atrophy was also present.

Keywords: Blindness, Intracranial tumor, Ischemia, Neurofibromatosis, Optic nerve glioma, Proptosis, Visual evoked potential

INTRODUCTION

The optic nerve is the most important cranial nerve responsible for vision, and it consist of approximately 1.2 million axons.¹ Optic nerve gliomas (ONGs) are usually pilocytic tumor that can involve the optic nerve or optic chiasma.² The ONGs comprises 5% of pediatric intracranial tumors.³ Primary tumor of the optic nerve is uncommon. ONG represent approximately 4% of all orbital tumors, 4% of all intracranial gliomas and 2% of all intracranial tumors. Gliomas are 4:1 more common than meningiomas.⁴ 20-30% of optic gliomas becomes symptomatic usually before age of 10 years.⁵

Most ONGs are slow growing and benign. Strong association has been found between ONG and neurofibromatosis. Symptoms usually seen in ONG are proptosis, squinting, vision loss. Visual evoked potential testing is a sensitive method for detection of asymptomatic optic gliomas. Treatment of optic gliomas should be tailored to the individual patient; no clear therapeutic protocol is available.⁶

CASE REPORT

We report an interesting case of 3-year-old male child, presented to us with dimension of vision in left eye since 6 months and painless outward bulging of left eye since 1 month. The child underwent a detailed, comprehensive ocular examination. Visual acuity was recorded first. The best-corrected visual acuity in right eye was 6/6 and in left

eye was 3/60. Detailed anterior segment examination by torch light and slit lamp was done. The right eye was within normal limit. The left eye showed presence of Proptosis (21 mm) (Figure 1) with exotropia (15). DeSousa *et al.* found in their study that 8 patients out of 29 had proptosis.⁷ Our patient also showed proptosis. This finding of proptosis in our patient correlated with the above-mentioned study. Detailed fundus photograph was recorded on Topcon fundus imaging system.

Fundus examination of left eye showed generalized disc pallor with well-defined margins suggestive of partial optic atrophy. Venous tortuosity was also present (Figure 2). The right eye was within normal limit.

The intraocular pressure was 15 and 22 mm of hg in right and left eye respectively.

The child was advised magnetic resonance imaging (MRI). The MRI report confirmed presence of ONG (Figure 3). The enlarged nerve sheath complex appears to be causing a widening of optic foramen and minimal mass affect on left superior ophthalmic vein.

The child was referred to neurosurgeon for further management.

DISCUSSION

ONGs are slow growing tumors which usually affect children under age of 20 years. ONGs represent 4% of all

Corresponding Author:

Dr. Anishi Agrawal, RMO Hostel, R.D. Gardi Medical College, Ujjain, Madhya Pradesh, India. Phone: +91-8103090365. E-mail: dr.anishi@gmail.com

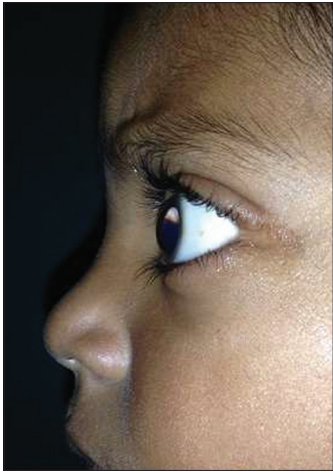

Figure 1: Proptosis

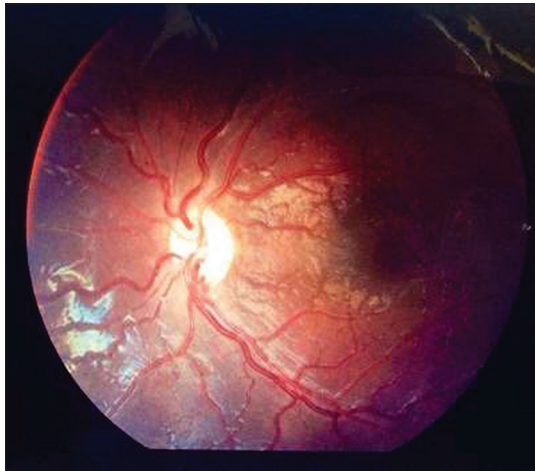

Figure 2: Partial optic atrophy with venous tortuosity

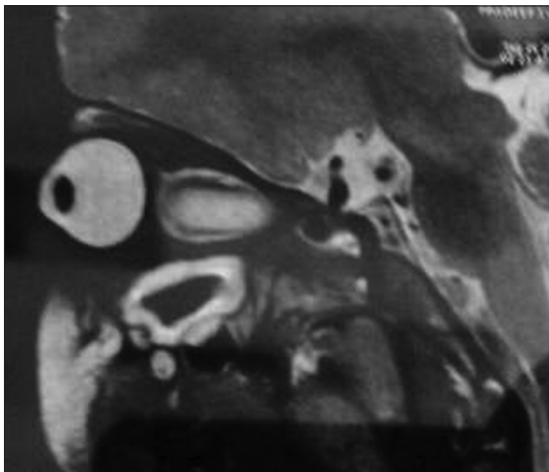


Figure 3: Magnetic resonance imaging showing presence of glioma

orbital tumors. On an average 20-30% of ONGs become symptomatic before the age of 10 years. ONG may be associated with neurofibromatosis. Visual evoked potential testing is sensitive method for detection of asymptomatic ONGs. The ONGs usually cause proptosis and blindness may gradually ensue.

ONG have various ocular presentation, they may be asymptomatic, or they may cause Proptosis or blindness through optic atrophy. Various modalities of management are available ranging from a conservative approach to a combination of radiotherapy, chemotherapy, surgical removal.

Our patient also had proptosis with disc pallor so was referred to neurosurgeon.

CONCLUSION

ONGs always create a great challenge to all ophthalmologists because of their wide variety of presentation. MRI should be done to reach proper diagnosis unless contraindicated.

Early diagnosis and proper management are advised to prevent blindness.

Lateral orbitotomy remains one of the best surgical approaches for removal of ONG.

REFERENCES

1. Sihote R, Tandon R. Parson's Diseases of the eye. 20th ed. New Delhi: Elsevier; 2007. p. 328.
2. Skelley N, Tao le, Bhushan V, William N. First Aid for the USMLE Step 2 CK. 8th ed. Los Angeles: McGraw Hill; 2012.2.
3. Janss AJ, Grundy R, Cnaan A, Savino PJ, Packer RJ, Zackai EH, *et al.* Optic pathway and hypothalamic/chiasmatic gliomas in children younger than age 5 years with a 6-year follow-up. *Cancer* 1995;75:1051-9.3.
4. Hollander M, Fitzpatrick M, Oconnor S, Flanders A, Tartaglino L. Optic gliomas. *Radiol Clin North Am* 1999;37:59-71.4.
5. North K, Cochineas C, Tang E, Fagan E. Optic gliomas in neurofibromatosis type 1: Role of visual evoked potentials. *Pediatr Neurol* 1994;10:117-23.
6. Oxenhandler DC, Sayers MP. The dilemma of childhood optic Glioma. *J Neurosurg* 1978;48:34-41.6.
7. DeSousa AL, Kalsbeck JE, Mealey J Jr, Ellis FD, Muller J. Optic chiasmatic glioma in children. *Am J Ophthalmol* 1979;87:376-81.

How to cite this article: Mehta S, Agrawal A, Chawla A. Optic nerve glioma with unilateral proptosis: An interesting case report. *IJSS Case Reports & Reviews* 2014;1(1):1-2.

Source of Support: Nil, **Conflict of Interest:** None declared.